A Case of Prostate Adenocarcinoma with Extracapsular Extension Treated with Radical Prostatectomy Followed by Therapy with Liquid Polyatomic Oxygen® (LPO)® and Procarbazine

G. BARCO*, M. MAMELI**, C. ADAMO***

* Chairman Eumedica Ozono; ** Scientific Advisor Eumedica Ozono; *** Chairman Italian Society of Penitentiary Medicine

Key words: prostate adenocarcinoma, liquid polyatomic oxygen®, (LPO)®, chemotherapy, procarbazine

SUMMARY - *Prostate tumours are the commonest cancer in many industrialized countries and the second cause of death among the male population after lung cancer. Prostate tumours affect 20-30% of men over the age of 50 years with a rising incidence due to the progressive ageing of the population - to the extent that 50% of men over 80 years have histological evidence of prostate cancer. Having successfully managed other tumours administering liquid polyatomic oxygen®, (LPO)®, we treated prostate adenocarcinoma with procarbazine, a cytotoxic methylhydrazine derivative, associated with chronic oxidative therapy (COT) obtained by continuous administration of (LPO)® rich in superoxide anion (O_2^-), using a micropump connected to a Groshong type central venous catheter positioned in the patient's subclavian vein. This new approach led to a complete resolution of the tumour which had been unresponsive to standard treatment following international protocols. The therapy had the additional advantage of allowing the patient to enjoy an excellent physical and mental quality of life during the treatment.*

Introduction

Ten years have passed since we treated our first patient with continuous stress we termed chronic oxidative therapy (COT). That patient had a neuroblastoma unresponsive to international treatment protocols. Today TOC still consists in the continuous administration even for months of a mixture of liquid polyatomic oxygen® (LPO)® rich in superoxide anion (O_2^-). LPO is administered via a micropump connected to a Groshong type central venous catheter. The aim of COT is to boost the activity of certain chemotherapeutic agents, namely dialchiltrazenes and methylmelamines that require a strongly oxidative environment to act on neoplastic cells. To date, COT has broadened the field of action of many chemotherapeutic agents, treating tumours hitherto difficult to manage with current therapies as in the case of advanced prostate cancer.

Case Report

A man born in 1953 who worked as a gardener underwent ultrasound examination of the prostate (figures 1-4) that disclosed a small central adenoma measuring 3 cm located in the right posterior portion of the gland. The tumour had an inhomogeneous structure and minute fibrocalcifications. On 18th June 2007 the PSA blood test showed levels of 6.10 ng/ml, while free PSA was 34.12 ng/ml tPSA (total prostate specific). On 25th July 2007 a transrectal needle biopsy of the prostate with specimens taken from the apex and base of the right and left lobes confirmed the prostate adenocarcinoma. The tumour had a medium-low degree (Gleason 4+3) of differentiation involving all the fragments examined (100% of tissue)[1-4] with clear-cut perineural invasion.

An MR scan using a transrectal coil on 13th September 2007 confirmed the presence of dyskaryokinetic foci with involvement of the periprostatic adipose tissue. Bone scintigraphy ruled out secondary lesions. The patient underwent surgery for radical prostatectomy and lymphectomy followed by an uneventful post-operative course. Histopathologic analysis confirmed the biopsy diagnosis of prostate adenocarcinoma, Gleason score 7(4+3), involving both lobes with extracapsular extension and infiltration of the seminal vesicles in both lobes. The tumour reached the limits of surgical resection in the left lobe. In addition,

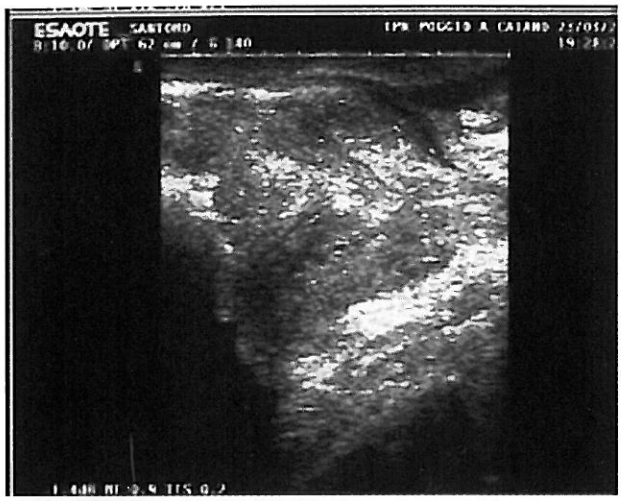

Figure 1

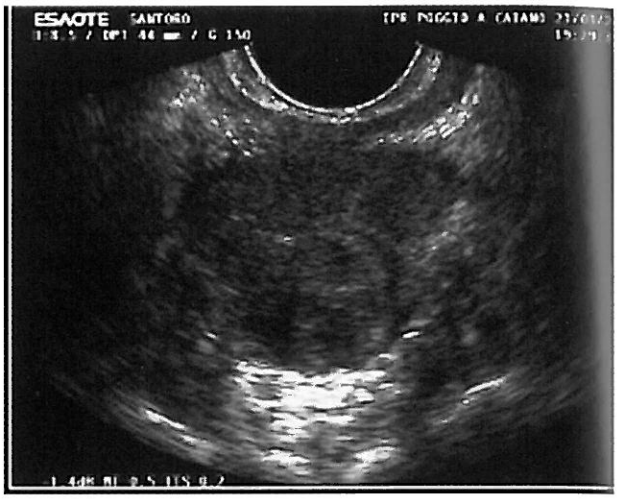

Figure 2

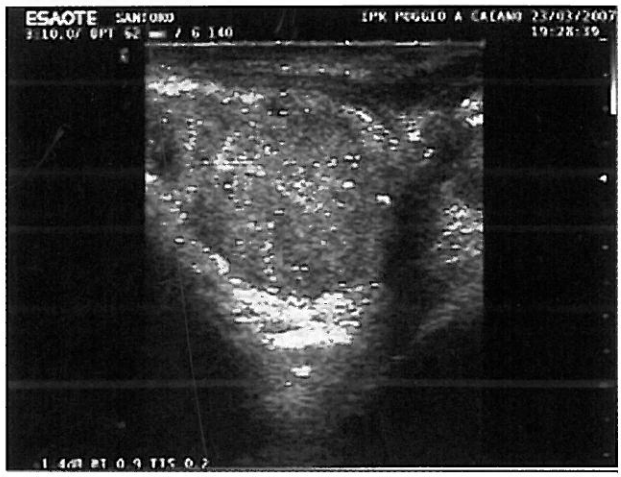

Figure 3

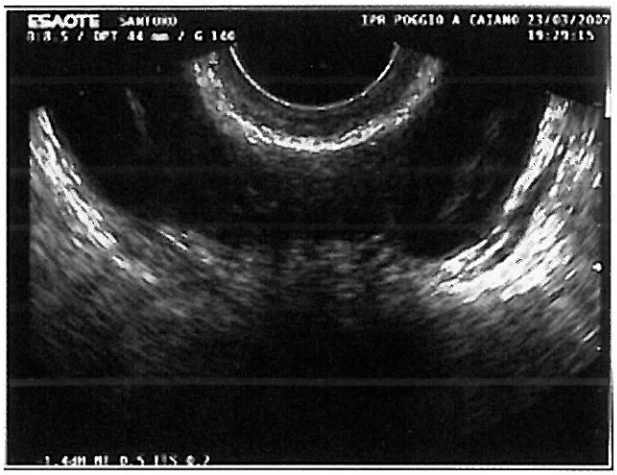

Figure 4

metastases were found in all ten iliac and obturator left and right lymph nodes examined. The pathological classification was pT3b pN1 pMx.

Like most solid tumours, the aetiology of prostate cancer is multifactorial, and hence is the outcome of a complex interaction between genetic and environmental factors including hormone status and age of subjects at risk. Genetic factors are responsible for familial recurrence and the different incidence of disease in different human races, rare in the Far East, common in the United States and extremely common among black populations in North America. The environmental factors responsible for prostate cancer include both diet, such as an excessive calorie intake and the overconsumption of animal fats, and the presence of certain environmental carcinogens, first and foremost cadmium.

At the moment it is difficult to act directly on the main risk factors for prostate cancer - age, race, endocrine system and environmental factors – so that effective preventive measures for the disease have yet to be implemented. Secondary prevention, however, i.e. early diagnosis, remains the only instrument available to try to reduce the mortality rate as the chances of successfully treating this type of cancer are greater when the tumour is still contained within the gland. However, early diagnosis remains a difficult medical policy to implement because most patients with localized prostate cancer are usually symptom-free and only the presence of bladder obstruction impairing urination will lead patients to undertake diagnostic tests. Currently available tests include clinical and instrumental examinations like rectal exploration, transrectal ultrasound, nuclear magnetic

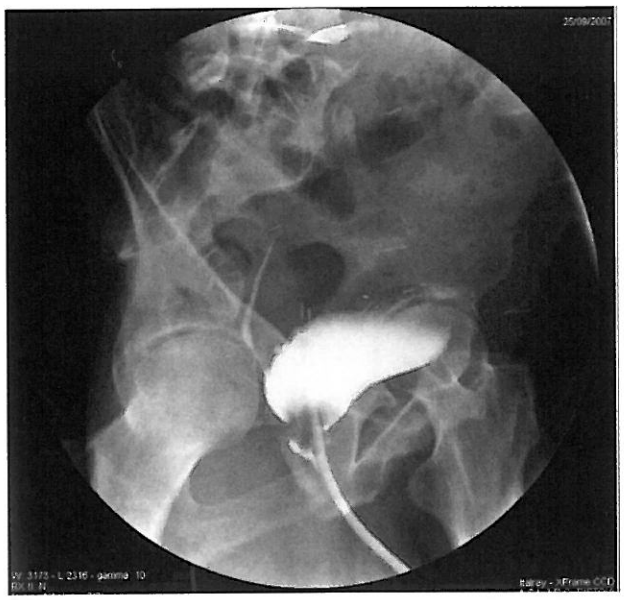

Figure 5

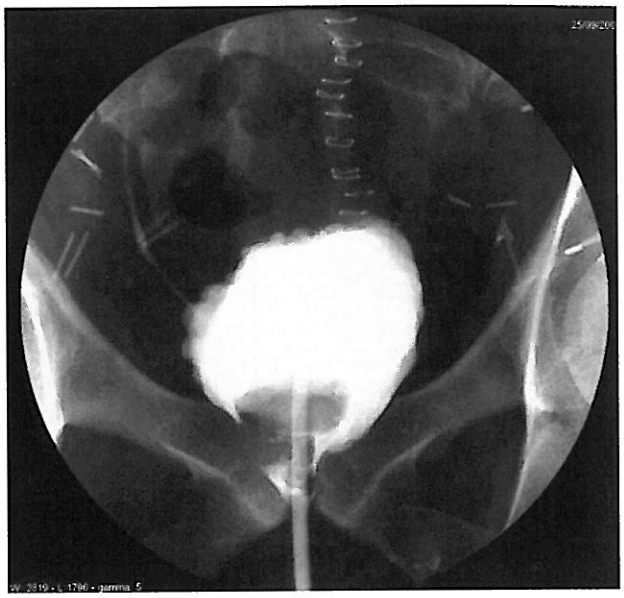

Figure 6

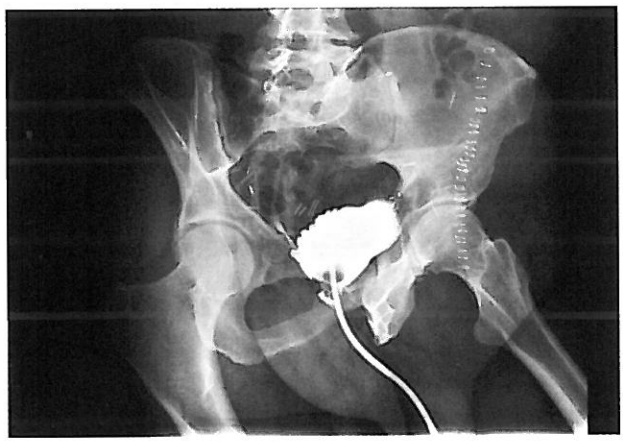

Figure 7

resonance with an endorectal coil, magnetic resonance spectroscopy, biopsy, etc., and laboratory tests, namely serum detection of prostate specific antigen (PSA).

PSA is a 33KDa serine protease synthetized and secreted largely by the prostate gland epithelium to fluidify the seminal fluid. It has been used as a marker of prostate cancer since 1986. The search for PSA is currently the only non-invasive test for the diagnosis of a microscopic prostate tumour, the form of adenocarcinoma most amenable to successful treatment when still confined. When a prostate tumour is present the blood level of PSA generally increases: PSA levels higher than 4 ng/ml of blood indicate the possible presence of prostate cancer, while levels higher than 10 ng/ml of blood are particularly indicative of disease. Nonetheless raised levels of PSA do not signify certain prostate cancer. Some diseases of the prostate other than cancer can raise PSA levels in blood, primarily benign prostatic enlargement or prostatitis, but also prostatic manipulation (rectal exploration, biopsy) or simple mechanical pressure on the organ may trigger elevated serum levels of PSA. By contrast, PSA levels are normal in many cancer patients at the time of diagnosis and half the individuals with high PSA levels do not have prostate carcinoma. In order to identify patients with cancer it is very important to have variations in PSA concentration from one year to the next, a test known as PSA velocity (PSAV).

Despite the limitations of the PSA test, with 96% specificity for prostate cancer and 80% sensitivity due to the high positivity in benign prostatic enlargement and prostatitis, PSA determination does not offer significant advantages in the early

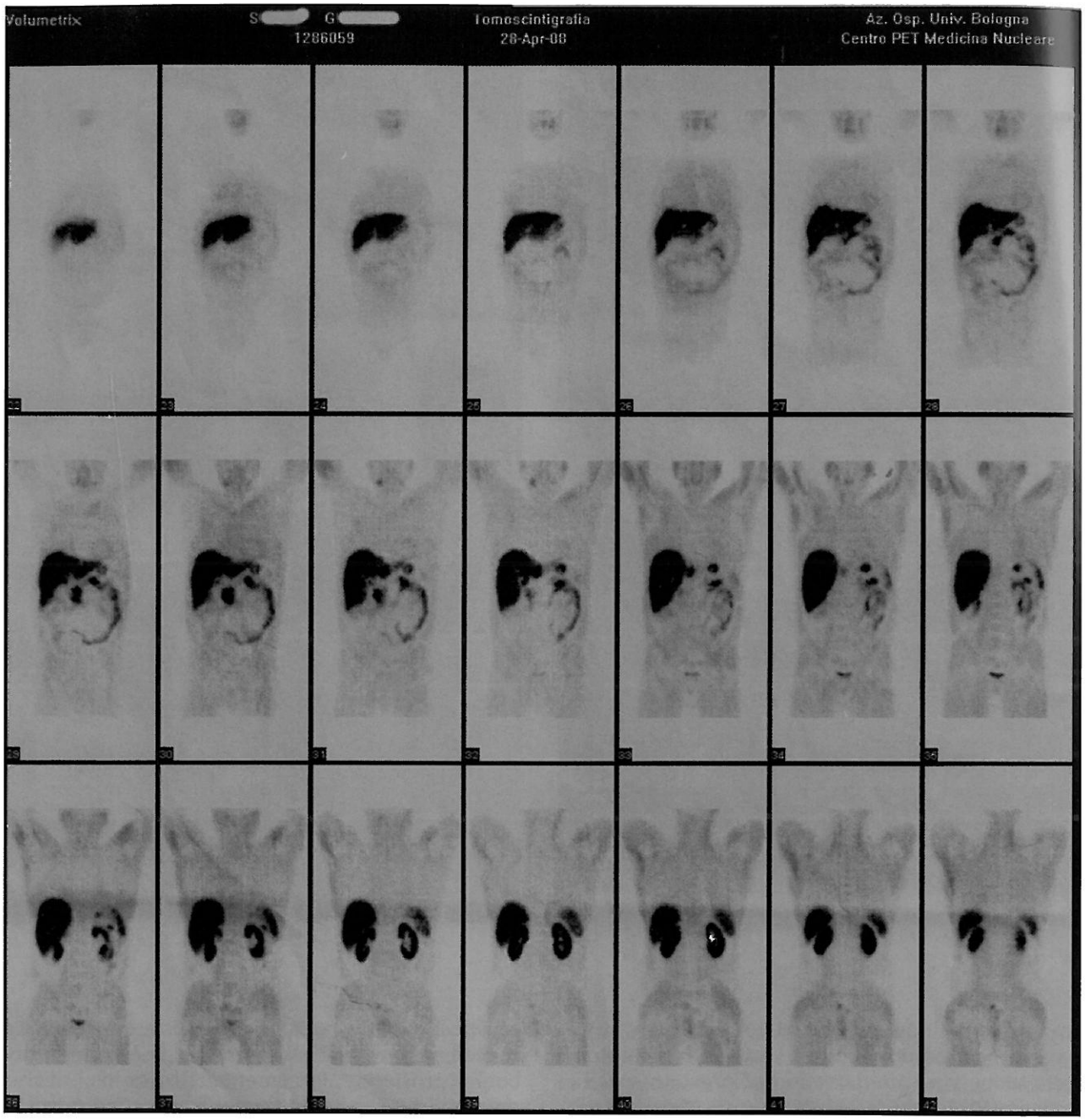

Figure 8

diagnosis of prostate cancer. Instead, PSA serves as a very useful adjunct in monitoring the clinical course of the disease to disclose both disease progression and disease recurrence during treatment. PSA levels rise with disease progression, drop if the disease subsides and fluctuate when the disease is controlled by treatment. If PSA can still be measured after radical prostatectomy then residual disease is present.

PSA levels could still be measured in our patient after surgery supporting a clinical picture of metastatic dissemination, confirmed by direct cystography (figures 5-7) with and without contrast administration showing a limited uptake of contrast medium with marked parietal irregularity of the bladder and marked bladder-right ureter reflux and opacification of the pelvis and ipsilateral calices (figure 2). The patient was treated

with gonadotropin releasing hormone analogue (GnRH analogue), an intramuscular phial of 11.25 mg/2 ml triptorelina (Decapeptyl) every three months associated with an androgen antagonist, bicalutamide (Casodex) 150 mg/die, immediately interrupted by the patient due to malaise and loss of consciousness.

Triptorelina inhibits LH release thereby suppressing serum levels of testosterone as in castrated subjects. The anti-androgen bicalutamide can block 10% of androgens produced by the adrenal glands. Oral androgen antagonists, including bicalutamide, are also used in the first month of therapy with GnRH analogues to block the rise in testosterone associated with the fall in LH levels. Even today, the administration of the gondotropin releasing hormone analogue associated with the anti-androgen is a treatment subject to clinical judgement. Whether the therapy should be applied in the early stages of disease when local therapy has failed, or only used to treat advanced prostate cancer or metastatic disease remains a matter of debate. Hormone therapy is commonly given in the earliest stages of disease, even though it has not yet been demonstrated whether early treatment prolongs survival. Despite heated discussions on the matter among clinicians, the fact is that advanced prostate adenocarcinoma treated with hormone therapy will in time lead to the emergence of androgen independence making it necessary to administer chemotherapeutic agents (extramustine, anthracycline, etc.). This is a second choice therapeutic approach which is usually disappointing and used only for palliative purposes.

Methods

After radical prostatectomy and lymphectomy, our patient was monitored by monthly PSA determinations. Despite a total androgen block, he had measurable levels of the marker one month after surgery. On 12th October 2007 he had a serum tPSA level of 3.67 ng/ml indicating disease progression as rises in PSA blood levels are 50% higher than the minimum values reached during hormone therapy. In addition, the patient complained of the typical complications of hormone therapy: hot flushes, impotence, weakness and weight increase.

On 7th November 2007 the patient agreed to oral administration after fasting of the methylhydrazine derivative procarbazine (PCZ) at a total dose of 150 mg daily divided into two 50 mg capsules in the morning on an empty stomach (eating two hours later) and one 50 mg at 16.00 again on an empty stomach (eating only after two hours). The treatment was given for seven consecutive days with 20 day intervals and treatment cycles of 27 days. Procarbazine is rapidly and completely absorbed in the gastrointestinal tract. It is a cytotoxic drug specific to the G2 phase of the cell cycle. After initial oxidation, from the hepatic microsomial system it undergoes metabolic activation. Through a process of isomerization procarbazine then forms an azoderivative, the methyldiazonium ion which has strong alkylating capacity and can degrade protein synthesis and consequently DNA and RNA synthesis. Much evidence indicates that the damage to cell nucleic acids caused by procarbazine is also due to the formation of oxhydryl and methyl free radicals. In addition, in vitro studies suggest that the drug not only blocks the Krebs cycle and oxidative phosphorylation, but also triggers aberrant transmethylations of DNA and t-RNA. For the active metabolite of procarbazine to be excreted by the kidney and to a lesser extent by the liver as an inactive metabolite, it must undergo a second oxidation.

Chronic oxidative therapy (COT) was administered concurrently with procarbazine treatment. COT was obtained by continuous administration of LPO® (liquid polyatomic oxygen®) particularly rich in superoxide anion (O_2^-). LPO is administered through a micropump connected to a Groshong type central venous catheter positioned in the patient's superior subclavian vein. The aim of COT is to change the redox potential of the extracellular and cytoplasmic environment to boost the therapeutic index of procarbazine by enhancing the oxidative activity required to excrete the drug and suppressed by induction of the hepatic microsomial system following repeated drug administration.

Results

On 28th April 2008 after two months of COT and tPSA levels no longer measurable, the patient underwent a total body scan (PET) with i.v. administration of 370 MBq of ^{11}C-Choline (figure 8) that disclosed a total absence of areas with pathological uptake of the radiotracer caused by the underlying disease.

After almost a year of continuous (24h/24h) administration of LOP ®, but especially in view of the absent serum levels of tPSA and the excellent health of the patient, COT was suspended on 24th September 2008 with removal of the Groshong central venous catheter.

The patient went back to his previous job and was advised to have three monthly check-ups for tPSA blood levels. At his last follow-up on 24th November 2008 his blood tests results showed absent serum levels of tPSA.

References

1 Iabichella ML, Gritly H, Adamo C et Al: Un caso di glioblastoma trattato con terapia combinata con temozolomide ed ozono in forma liquida somministrato in continuo per via venosa centrale. Rivista Italiana di Ossigeno-Ozonoterapia 4: 159-164, 2005.
2 Beratan D: Tunnel degli elettroni nell'acqua. Science 2005.
3 Barco G: Un caso di linfoma non-Hodgkin non responsivo alle comuni terapie e trattato con terapia ossigeno poliatomico liquido (OPL) somministrato in continuo per via venosa centrale e temozolomide. Rivista Italiana di Ossigeno-Ozonoterapia 6: 157-162, 2007.

G. Barco, MD
Via Hermada, 15
56127 Pisa, Italy
E-mail: giovanni.barco@libero.it